




Contents lists available at ScienceDirect

## Journal of the Neurological Sciences

journal homepage: [www.elsevier.com/locate/jns](http://www.elsevier.com/locate/jns)

## CNS Infections

272

WFN15-1149

## CNS Infections

## Tuberculosis of the central nervous system and literature review

N. Abdelkafi, M. Aissi, F. Bouatay, I. Mahmoud, S. Khalfaoui, M. Ayed-Frih. *Neurology, Fattouma Bourguiba Hospital, Monastir, Tunisia*

**Introduction:** As is well known, tuberculosis (TB) can affect multiple organ systems, the most common being pulmonary. However, research shows that as many as 10% of persons with pulmonary TB develop central nervous system (CNS) TB, which can manifest as meningitis or lesions of the brain or spine.

**Aim:** to describe the possible presentations of CNS TB, review diagnostic and laboratory studies, and explain treatment options.

**Settings and design:** it was a hospital-based retrospective descriptive study.

**Methods and material:** 5 patients with CNS TB were enrolled in the present study.

**Results:** 5 patients were included in this study. Amongst these patients, 3 were male and 2 were female with age ranging from 27 years to 64 years (mean age 37.8 years). Two patients were admitted for subacute spinal cord compression with tuberculous meningitis and magnetic resonance imaging (MRI) of the spine showed a ring-enhancing intramedullary mass with vasogenic edema. The third patient was admitted to explore vertigo and radiologic explorations conducted to brainstem expensive process. The fourth patient was admitted in our department for a bulbar brain syndrome. The cerebral MRI showed a lesion on T2 in the left medulla oblongata which took gadolinium annularly. The last patient has presented a tuberculous meningo-encephalitis with a normal MRI. Anti-tuberculosis drugs and corticosteroid therapy were administered with good evolution in all patients.

**Conclusion:** Although CNS TB is a rare complication of TB, it is a serious disease, and early recognition and treatment are imperative. It can present in several ways and early diagnosis can prevent further deterioration and result in better prognosis.

doi: [10.1016/j.jns.2015.08.348](https://doi.org/10.1016/j.jns.2015.08.348)

273

WFN15-0355

## CNS Infections

## Clinical benefit of the prion protein gene screening

E. Abe<sup>a</sup>, C. Wada<sup>a</sup>, T. Hatakeyama<sup>a</sup>, F. Takeda<sup>a</sup>, K. Obara<sup>a</sup>, M. Kobayashi<sup>a</sup>, T. Imota<sup>a</sup>, S. Kamada<sup>b</sup>, M. Sugawara<sup>b</sup>, M. Ogasawara<sup>c</sup>, S. Mamiya<sup>d</sup>, I. Toyoshima<sup>a</sup>. <sup>a</sup>*Neurology, National Hospital Organization Akita Hospital, Yurihonjyo, Japan;* <sup>b</sup>*Neurology, Akita University, Akita,*

*Japan;* <sup>c</sup>*Rehabilitation, Oyu-Onsen rehabilitation Hospital, Kazuno, Japan;* <sup>d</sup>*Intermedicine, National Hospital Organization Akita Hospital, Yurihonjyo, Japan*

Approximately 20% of prion diseases in Japan are associated with mutations in the prion protein (PRNP) gene. We hereby report a case with fCJD V180I, a case with fCJD M232R and two cases with GSD P102L.

Case 1 with V180I and case 2 with M232R had no family history. Clinical features of both cases were similar to sporadic CJD (sCJD). Their diffusion-weighted imaging (DWI) brain MRI showed hyperintense signal in the cerebral cortex. Case 3 was a 61-year-old woman. When she was 47 years old she showed nystagmus, truncal ataxia, and pyramidal tract signs but no dementia. Her symptoms were similar to Machado-Joseph disease (MJD). DWI brain MRI showed no abnormality during the early stages. She developed akinetic mutism 9 years after onset and died 3 years later. Case 4 was the older brother of case 3. He noticed painful dysesthesias of his lower limbs at 59 years old. 2 years later he showed truncal ataxia and mild dementia. He developed akinetic mutism 6 years after onset and died 1 year later. The pathological findings of case 4 showed spongiform changes in the cerebral cortex and amyloid-like plaques in the cerebellum. We detected P102L mutation in the PRNP gene.

Some of the CJD cases without family history have the PRNP gene mutations, and DWI brain MRI sometimes show no hyperintense signal change. We should analyze the PRNP gene because inherited prion diseases show various phenotypes.

doi: [10.1016/j.jns.2015.08.349](https://doi.org/10.1016/j.jns.2015.08.349)

274

WFN15-1281

## CNS Infections

## The clinical and epidemiological profile of neuroschistosomiasis

R. Amaral, A. Andrade Filho. *CNS infections, Neurology and Neurosurgery Foundation/ Brain Institute, Salvador, Brazil*

This study aimed to describe the clinical and epidemiological profile of the neuroschistosomiasis (NS), evaluate the possible resistance of black people to NS, identify the cause of major prevalence of male sex and the parasitological stool exam as a proof of contact with NS. It is a cross-sectional study evaluating patients treated in neurological referential centers in Salvador, Bahia, Brazil, from 1993 to 2013. This study included patients diagnosed with schistosomal myeloradiculopathy by means of positive epidemiology, evidence of medullar lesion by image exam and clinical exam and cerebrospinal fluid analysis. There were 140 patients, 53% between 20 and 40 years old (mean=36; SD=13), 64% males. Among these patients, 79.3% received less than 05 minimum wages and only 5.7%

attended higher education. They were 50% brown, 27% white, 18% black, and 5.2% denied previous contact with water in endemic localities. The most prevalent clinical manifestations were weakness in the lower limbs (94%), back pain (84%), bladder dysfunction (75%) and impotence (80%). The most common site of injury was the thoracolumbar junction (65%) and 73% of parasitological stool examinations were negative. It was concluded that male predominance does not seem to occur because of specific physiopathological issues; possible resistance of Blacks to severe forms of schistosomiasis does not seem to occur in NS; the low economic and educational levels makes this problem invisible to the nation; the absence of water contact patterns does not completely rule out the diagnosis; the parasitological stool examination is a bad predictor of contact with NS.

doi:10.1016/j.jns.2015.08.350

275

WFN15-1256

CNS Infections

**CNS tuberculosis in patient with previous non-hodgkin's lymphoma: case report of a challenging diagnosis**

P.C. Azevedo<sup>a</sup>, A.A.V.O. Sousa<sup>a</sup>, L.G. Borges<sup>a</sup>, T.A.M.O. Cardoso<sup>a</sup>, A.C.S.A. Filho<sup>b</sup>, M.R. Lazzarato<sup>c</sup>. <sup>a</sup>Neurology, UNICAMP, Campinas, Brazil; <sup>b</sup>Radiology, UNICAMP, Campinas, Brazil; <sup>c</sup>Infectology, UNICAMP, Campinas, Brazil

**Background:** One third of world's population has a tuberculosis infection and 10% will develop active disease. CNS tuberculosis is rare, but has a high mortality and morbidity. It can present in multiple forms, many times, mimicking other diseases.

**Objectives:** To report a case of CNS tuberculosis in a patient with history of Non-Hodgkin's Lymphoma.

**Patients and methods:** Brain CT and MRI were performed and CSF was collected. A brain biopsy was realized.

**Results:** A 72 years-old female was treated for diffuse large B-cell Lymphoma, and was being followed by cure, when presented with seizures, left hemiparesis and dizziness. Image testing showed expansive lesion in right parietal lobe. The brain biopsy showed granuloma and excluded cancer and infection by fungus, toxoplasma or Micobacterium (negative culture). The CSF presented 2 cells, protein 52, Glucose 92 (serum 126), normal ADA and negative cultures. She was treated first for CNS toxoplasmosis, showing no clinical or image improvement after a few months. Brain biopsy was, then, tested for tuberculosis with HEINE technique and was positive. The patient had full recovery of deficits after initiating the treatment, but died after 3 months due to pulmonary complications of tuberculosis.

**Conclusion:** CNS tuberculosis is a challenging diagnosis, needing multiple forms of investigation tests. It is important to maintain a high level of suspicion in patients with history of immunosuppression.

doi:10.1016/j.jns.2015.08.351

276

WFN15-0250

CNS Infections

**Osteomyelitis and destruction of the atlas and axis in a 4-week old infant. How is neck movement is possible?-5-years follow up**

P. Banczerowski<sup>a</sup>, G. Czigléczi<sup>b</sup>, M. Simó<sup>c</sup>, Z. Papp<sup>a</sup>. <sup>a</sup>Dept. of Spine Surgery, National Institute of Clinical Neurosciences, Budapest, Hungary; <sup>b</sup>Dept. of Neurosurgery, Semmelweis University, Budapest, Hungary; <sup>c</sup>Dept. of Neurology, Semmelweis University, Budapest, Hungary

**Background:** C1-2 osteomyelitis is a very rare entity even in children. Osteomyelitis simultaneously involving the atlas and the axis is distinctly unusual.

**Objective:** We present the case of an infant with retropharyngeal abscess, which led to the destruction of the C1-2 vertebrae.

**Methods:** The infant presented with fever, tachycardia, hypersalivation, and muscular hypotension. MRI revealed a multilocular abscess in the mastoidal area penetrating to the cervical region and causing destruction of the C1 and C2 vertebrae, and an epidural abscess with signs of spinal cord compression at the level of the Th5-7 vertebrae. Sepsis, encephalomyelitis and left-sided hemiparesis appeared. The retropharyngeal and thoracic abscesses were surgically removed and the therapy was completed with antibiotics. The child was placed in a custom-made fixation device for 8 weeks.

**Results:** CT scans demonstrated the absence of normal osseous structures at the cranio-spinal region, but undamaged ossification centers in the C3 vertebra and below. Normal motor development and independent walking were allowed. During a 5-year-long follow-up period, no signs of neurological impairment were observed, neck movements were limited but painless. It is assumed that the remnants of the bony elements of C1-2 vertebrae and the massive interconnecting post-inflammatory scar tissue make some degree of neck movements possible.

**Conclusion:** There is limited experience with treatment, but temporary immobilization of the neck, surgical debridement, antibiotic treatment and fiziotherapy can be recommended. Close follow-up is required to check the reconstitution of affected bones and ligaments, any development of instability, and the necessity of surgical stabilization.

doi:10.1016/j.jns.2015.08.352

277

WFN15-1347

CNS Infections

**Neurobrucellosis with meningoradiculopathy**

L.la. Ben Eljia, A.is. Hassine, A. Bouthouri, S. Ben Amor, I. Chatti, A.sa. Khefifi, S. Ben Ammou. Neurology, University Hospital Sahloul, SOUSSE, Tunisia

**Introduction:** Neurobrucellosis manifestations occur in about 5% of all brucellosis cases. They tend to be chronic and protean. Early diagnosis and treatment are necessary.

**Case report:** A 17-year-old was admitted with complaints of progressive lower limb weakness present for 2 months. Upper limb motor functions were normal. The neurological examination found lower limbs motor deficit affecting essentially proximal muscles: he couldn't walk without unilateral aid. The tendon reflexes were absent in the lower limbs. There was no sensitivity disturbance. Cerebrospinal fluid examination found 300 leucocyte/mm<sup>3</sup> composed by 60% of neutrophils polynuclear and 40% lymphocytes and hyperproteinorrachia at 0.6 g/l. Serology was positive for brucellosis in the blood and in the cerebrospinal fluid. the brain and spine MRI were normal. the radiculopathy was confirmed by electromyogram and patient was treated by doxycycline and rifadine. partial recovery was obtained.

**Discussion:** Neurological involvement due to brucellosis can be central or peripheral. It can occur without the systemic symptoms of the disease. Neuropathy and radiculopathy represent 20% of the neurobrucellosis symptoms. It is especially due to axonal lesions. Generally it has a good response to the appropriate antibiotic treatment.

**Conclusion:** Neurobrucellosis involvement is a serious complication of brucellosis and its clinical presentation is heterogeneous. the contribution of the examination and serology allow early treatment to avoid irreversible damage.

doi:10.1016/j.jns.2015.08.353

279

WFN15-0187

**CNS Infections****The probable role of several infective agents in multiple sclerosis**

N. Botchorishvili, N. Lobjanidze, N. Akiashvili, M. Beridze, N. Kvirkvelia. *Neuromedicine, S.Khechinashvili Medical University Hospital, Tbilisi, Georgia*

Study purposed to investigate the role of several infective agents in multiple sclerosis.

**Patients and methods:** Fifty nine patients with MS have been investigated. Among them the first group -19 patients with primary progressive MS, the second group-24 patients with relapse remitting MS and the third group-16 patients with secondary progressive MS. Several infections (Chlamydia pneumoniae, mycoplasma hominis, herpes virus 6) were detected in 4ml CSF. DNA was isolated from CSF and PCR method according to kit instruction (Amplification > 15 kb, temperature over 65°C- Maximbio, USA). The length of the DNA was detected by agarose gel electrophoresis. CSF oligoclonal bands were detected by agarose gel electrophoresis with Coomassie Blue staining. Statistics performed by SPSS-11.0.

**Results:** Chlamydia pneumoniae found to be positive in CSF of 11 (45%) patients with relapse remitting MS and in 7 (43%) patients with secondary progressive MS. Mycoplasma hominis was positive in CSF of 2 (8%) patients with relapse remitting MS. Herpes virus 6 was positive in 1(5%) patients with primary progressive MS and in 1(5%) patient with secondary progressive MS. Positive correlation was found between presence of CSF Chlamydia pneumoniae and CSF count of oligoclonal bands ( $r = +0.27$ ,  $p < 0.01$ ).

Multiple logistic regression analysis revealed the significance of infective agents for mean predicted probability of development of relapse remitting MS.

**Conclusion:** Probably, infective agents play the important role in immunology and clinical course of MS.

doi:10.1016/j.jns.2015.08.354

280

WFN15-1329

**CNS Infections****Cryptococcus neoformans meningitis in a heart transplanted patient difficult diagnosis: a case report**

J. Celis<sup>a</sup>, P. Gonzalez-Obando<sup>a</sup>, G. Roncancio Villamil<sup>b</sup>, G. Gonzalez<sup>b</sup>, A.M. Quintero-Ossa<sup>c</sup>, M.C. Velez<sup>d</sup>, E. Sanchez<sup>d</sup>. <sup>a</sup>Neurology, Neurology Service Clinica Cardio Vid / Universidad Pontificia Bolivariana School of Medicine, Medellin, Colombia; <sup>b</sup>Infectology, Infectology Service Clinica Cardio Vid / Universidad Pontificia Bolivariana School of Medicine, Medellin, Colombia; <sup>c</sup>Cardiology/Heart Transplantation Program, Clinica Cardio Vid / Universidad Pontificia Bolivariana School of Medicine, Medellin, Colombia; <sup>d</sup>School of Medicine, Universidad Pontificia Bolivariana School of Medicine, Medellin, Colombia

**Background:** CNS disorders in heart transplanted (HT) can occur, most delirium, seizures, headache; infections are less frequent most CMV, post-transplant lymphoproliferative disorder (PTLD) TB, *C. Neoformans*, Epstein Barr Virus, *Listeria*.

**Objective:** To present a patient HT with a meningitis due to *C. Neoformans* with difficult diagnosis.

**Case presentation:** 69 YOM HT, on Prednisolone-Tacrolimus, was admitted with lacunar stroke left posterior internal capsule. A 4 month global daily headache, no fever. Embolic/athero sources were disclosed, small vessel disease suspected. Readmitted with cognitive decline and gait disorder. CT no new lesions. LP performed: pleocytosis 45 mono, proteins > 300 mg/dL, glucose 20 mg/dL, open pressure: 25, ADA: 4, RCP TB negative. Epstein Barr, Herpes, CMV, negative, Cryptococcus also

negative but antigen in blood positive, put on Anfotericine B, no tolerated, several LPs no Cryptococcus, treatment stopped. Patient continues deterioration, on MRI many white matter lesions, brainstem stroke, no alterations on Angio-MR. A PTLD was suspected, total body PET Scan no malignancies. Meningeal cerebral biopsies were done, nonspecific chronic inflammation. Finally Cryptococcus antigen on CSF, put on Anfotericine B and chronic meningitis diagnosis.

**Discussion:** CNS infections most of the time can be diagnosed rapidly in immunocompetent host (IC) and difficulties occur in not IC as presented with this case due to a *C. Neoformans* with a severe vasculitis of CNS, started as a lacunar stroke and 5 months later diagnosis could be done.

**Conclusion:** Non IC hosts are a challenge when making diagnosis, specially in transplanted patients where immunosuppressants can cause adverse effect, complicating diagnosis.

doi:10.1016/j.jns.2015.08.355

281

WFN15-1061

**CNS Infections****Cytomegalovirus associated transverse myelitis in immunocompetent patient: case report**

H. Efendi, H. Bickin, D. Bunul. *Neurology, Kocaeli University, Kocaeli, Turkey*

**Background:** Acute transverse myelitis (TM) is a focal inflammatory disorder of the spinal cord with sensory, motor and autonomic dysfunction. Cytomegalovirus (CMV)-associated transverse myelitis is rare in the immunocompetent host. We describe an immunocompetent patient with atypical transverse myelitis and encephalitis associated with CMV infection.

**Case report:** A twenty year old previously healthy female presented with acute onset bilateral leg and arm weakness and numbness. She had never received immunosuppressive or irradiation treatment. Magnetic resonance imaging study of the spine showed hyperintensity of central and posterior portion of all spinal cord in T2 weighted and FLAIR images. Brain MRI showed hyperintensity of left inferior cerebellum and right frontal subcortical areas in T2 weighted. Spinal cord and brain MRI were no enhancement with contrast. Serologic tests ruled out an acute infection with HIV, herpes simplex viruses varicella-zoster virus, Epstein-Barr virus, measles and mumps viruses, toxoplasma gondii, and Treponema pallidum. Brucella Coombs, Brucella Wright agglutination tests were negative. Both anti-CMV IgM and IgG were elevated in the serum. However, a more sensitive assay resulted in low IgG avidity, suggesting primary CMV infection.

**Conclusion:** Our patient had evidence of spinal cord inflammation evidenced by CSF pleocytosis and MRI appearance. Infectious, para-infectious or post-vaccinal states, multiple sclerosis, or autoimmune disorders are the possible causes of TM. In some cases, the TM is presumed to be caused by viral infections. Cytomegalovirus (CMV) can cause severe disease in immunocompromised patients, either via reactivation of latent CMV infection or via acquisition of primary CMV infection. CMV-associated transverse myelitis is rare in the immunocompetent host.

doi:10.1016/j.jns.2015.08.356

282

WFN15-1514

**CNS Infections****Aseptic meningitis. A local experience**

I. Elicer Coopman, F. Del Rio Gomez. *Neurology, Hospital Sótero Del Río, Santiago, Chile*



**Background:** Aseptic meningitis is a serous inflammation of meninges, with lymphocyte-predominant pleocytosis in the cerebrospinal fluid. Clinical manifestations include acute headache, meningeal signs and fever, in a patient with no septic appearance. Prognosis depends on the subjacent cause.

**Objective:** Review the epidemiological and clinical characteristics of adult patients diagnosed with aseptic meningitis. Describe CSF findings, and etiologic study performed.

**Patients and methods:** Over a 6 months period, 9 patients with confirmed aseptic meningitis were included. Data was obtained from medical records. Patients with normal CSF, not evaluated by a neurologist or imaging suggesting other diagnosis, were excluded. IRB approval was obtained.

**Results:** 7 cases were women. Mean age was 37 years. Main symptom was headache. 2 cases presented some degree of impairment of consciousness. 1/3 had neck stiffness. None had fever or rash. 2/3 had normal Leukocytes and CRP. Mean WCC was 98 cel/mm<sup>3</sup> (with >95% monocytes); mean CSF protein 0,98 g/L, and 2 cases had CSF/serum glucose ratio of <0.4. In only 3 patients, viral PCR was performed, of which 1 was positive for HSV-2. One case was diagnosed with carcinomatous meningitis, and 2 cases with autoimmune etiology. 4 patients were treated with intravenous acyclovir.

**Conclusion:** Aseptic meningitis occurred mostly in young adults. No patient presented fever and few had meningeal irritation signs. Most had normal systemic inflammatory parameters. There was insufficient etiologic study; only in 1/3 of the cases viruses were investigated. Acyclovir may be overused. Etiological study is needed, to rationalize use of antiviral and establish prognosis.

doi:10.1016/j.jns.2015.08.357

283

WFN15-1362

CNS Infections

Post-herpetic radiculoneuritis

S. Gomes. *Neurology, B. Portuguesa, Sao Paulo, Brazil*

**Post-herpetic radiculoneuritis S**

**Introduction:** Herpes zoster (HZ) is a relatively common infectious disease and its incidence ranges from 1.3 to 3.4 cases per 100,000 in the general population. Herpes zoster is a disease caused by the reactivation of varicella-zoster virus in cranial nerve and dorsal root ganglia of the spinal nerves, usually triggered decades after primary varicella infection. Reactivation usually occurs in immunocompromised individuals and in immunocompetent elderly due to a compromised immunity mediated by T cells. Postherpetic neuralgia (PHN) is a complication of HZ characterized by pain in the distribution of dermatomes and can cause major morbidity for the patient.

**Objective:** To report an unusual case of HZ who developed postherpetic neuropathy.

**Case report:** Female patient, 82, appealed to the hospital with a condition of 41 days of pain in the right lower limb in the territory of L5-S1 and was hospitalized for five days to perform pain management. Ten days later showed persistence of pain symptoms with decreased strength in the right leg and falls. In new health care vesicular lesions were observed in the posterior region of the buttocks and right thigh, making diagnosis of HZ. Patient was again admitted and started ganciclovir, gabapentine and duloxetine. On the nine hospital day showed improvement of pain and paresis. In the thirteenth two day showed postural instability and Romberg sign, and decided to keep ganciclovir for 21 days. Patient developed global clinical improvement and was discharged but remained with intermittent pain and swelling in his left foot.

**Discussion:** The HZ is a self-limiting disease, but major complications and sequelae may occur.

doi:10.1016/j.jns.2015.08.358

284

WFN15-0478

CNS Infections

3 cases of neurosarcoidosis: unusual prestations and associations

H.H.M. HamdallaMD.FRCPC, M. HaqMRCP. *Neurology, Salford Royal Foundation Trust, Salford, United Kingdom*

Neurosarcoidosis is seen in approximately 10–25% of patients with systemic sarcoidosis. It potentially mimics other chronic diseases of the nervous system.

We are presenting three cases who presented with different neurological syndromes and biopsy proven diagnosis of sarcoidosis.

43 year old lady with intermittent headaches and papilloedema. CT venogram normal.

CSF opening pressure 31. CSF WCC 38 (polymorph 65%, lymphocytes 35%), protein 1.72, glucose 0.9 (serum glucose 5.7). CSF cryptococcal Ag, AFB, TB cultures and cytology was negative.

MR brain with contrast showed leptomeningeal enhancement in posterior fossa.

CT chest showed mediastinal lymphadenopathy.

EBUS aspirate: Granulomas with no evidence of necrosis or caseation. Started on steroids and mycophenolate with good response.

Case 2. 52 year old gentleman admitted with headaches and seizures. CT brain showed extensive venous sinus thrombosis.

CT thorax showed lymphadenopathy.

EBUS aspirate shows well-formed granulomas consistent with sarcoidosis or TB. TB test negative.

He had good response to anticoagulation and antiepileptics.

Case 3. 67 year old male with 3 months of burning sensation affecting different parts of the body. Clinical suspicion of mononeuropathy multiplex.

NCS no evidence of large fiber neuropathy or mononeuropathy multiplex.

He developed renal failure and the renal biopsy showed granulomatous interstitial nephritis consistent with sarcoidosis. CT scan of the chest was compatible as well.

Started on steroids and mycophenolate which improved his sensory symptoms.

Conclusion: To diagnose neurosarcoidosis, keeping low threshold, exclusion of other neurological disease and histological confirmation are required.

Figures: MRI brain (case 1), CTV (case 2) and histology (case 3).

doi:10.1016/j.jns.2015.08.359

287

WFN15-0880

CNS Infections

Ebola viral encephalitis and myelitis

D.A. Labunskiy. *Biomedical Engineering, University of Northern California, Santa Rosa, USA*

Ebola Virus Disease (EVD), formerly known as Ebola Haemorrhagic Fever, is a severe, often fatal illness in humans. To the best of our knowledge there is no link between Ebola and Encephalitis.

Recent evidence suggests converging pathways through which viral infection, and its associated immune surveillance processes, may alter integrity of the BBB, and lead to inflammation, swelling of the brain parenchyma and associated neurological syndromes.

Classical presentation is as a triad of fever, headache and altered mental state. There may be other findings either on examination or on imaging which, together with a travel history, may give clues as to the aetiology. It is important to note that in high- and middle-income countries the commonest cause of viral encephalitis is herpes simplex and Ebola.

The organs of monkeys infected with Ebola haemorrhagic fever were examined by light and electron microscopy during the acute stage

of disease. The virus caused focal coagulative necrosis in liver, spleen, kidney, lung and testis and widespread mild vascular damage. In brain there was intense congestion, with erythrocyte 'sludging', but no inflammatory reaction, significant injury to microvasculature in all organs. Virus replicated in endothelial cytoplasm causing focal necrosis, separation of tight junctions and detachment from basement membranes. These changes were associated with oedema and haemorrhage, contributing to hypovolaemic shock were not sufficiently extensive to account for severity of vascular collapse.

Therefore, alongside with chest and abdominal pain, cough, conjunctivitis, jaundice, pancreatitis, lymphadenopathy, delirium, and coma, other complications after second week of infection include transverse myelitis and encephalitis.

doi:10.1016/j.jns.2015.08.360

288

WFN15-0743

CNS Infections

Creutzfeldt jakob disease - a genetic form

T. Svrčinová<sup>a</sup>, J. Mares<sup>a</sup>, Z. Mouchová<sup>b</sup>, P. Kanovsky<sup>a</sup>. <sup>a</sup>Neurology, University Hospital Olomouc, Olomouc, Czech Republic; <sup>b</sup>Clinical pathology and molecular medicine, Thomayer Hospital, Prague, Czech Republic

**Background:** A genetic form of Creutzfeldt Jakob disease (CJD) is caused by a missense mutation in the prion protein (PRNP) gene. In a more than 70 per cent it is caused by E200K mutation, in this case the disease shows an incomplete penetration (63–75 %). Deciding factors of a manifestation of the disease in mutation bearers are not entirely clarified.

**Objective:** To report a case of patient with genetic form of CJD.

**Methods:** Detailed clinical and laboratory examinations and post mortem neuropathological examinations.

**Results:** We documented a case of a forty nine years old woman treated for an invasive ductal carcinoma. She was treated by radiotherapy and a hormonal therapy. In next six months the patient developed symptoms like a progressive dementia, a tremor, a myoclonus in facial and lower limbs, extrapyramidal and cerebellar signs. We have considered a paraneoplastic syndrome due to oncology history or other neurodegenerative disease at first. However, we have expressed a suspicion of a prion disease in regard to other clinical signs and results of examinations. The prion disease was confirmed post mortem by neuropathological, immunohistochemical, immunological and molecular genetical examinations. There was proved a mutation E200K (GAG>AAG) in a heterozygous state.

**Conclusion:** We documented a genetic form of CJD with the most common E200K mutation. Due to the incomplete penetration it is important to trace possible risk factors. With an exception of a lifestyle and infections, an oncology history is a very important factor affecting a manifestation of genetic CJD.

doi:10.1016/j.jns.2015.08.361

289

WFN15-0279

CNS Infections

Ataxia as a presenting sign of neurotuberculosis - a rare case

G. Mondal, S. Ghosh, K. Ghosh, R. Bhattacharya. *Neuromedicine, Calcutta National Medical College, Kolkata, India*

**Introduction:** CNS tuberculosis is a devastating disease involving any part of it. We present a rare and possibly first case of tuberculous cerebellitis diagnosed by cerebrospinal fluid PCR.

**Case:** A 28 year old female, with no known co-morbidities, presented with unsteadiness of gait for 5 years which progressed to postural imbalance over last 3 months accompanied by scanning speech. There was no history of fever, arthralgia, loss of consciousness, seizures, weakness of either side of body, sphincter dysfunction, sensory loss, visual disturbances, bulbar symptoms or memory deficits. There was no relevant history of drug ingestion or history of similar illness in her family or history of contact with TB or STDs. On neurological examination, higher mental functions were normal except for scanning speech, no cranial nerve deficits, no sensory abnormalities. There was mild hypotonia in lower limbs. Cerebellar signs were evident in form of truncal ataxia, dysmetria and pendular knee jerk. Romberg's sign was negative. There were no abnormal movements, no meningeal signs, no trophic changes and neck and spine was normal. Routine blood investigations were normal. RFT, LFT and electrolytes were normal. Anti nuclear antibody (ANA) was negative. MRI brain revealed diffuse cerebellar atrophy. CSF study revealed 10 lymphocytes, raised protein (182 mg/dl), decreased sugar (40 mg/dl with simultaneous RBS -95 mg/dl), negative gram stain and culture, and normal Adenosine Deaminase Activity (ADA). The CSF PCR study was positive for *Mycobacterium tuberculosis*. Mantoux test revealed 9 × 10 mm induration. CXR(P/A) and Ultrasonography of abdomen were normal. NCS of lower limbs was normal. Genetic testing for Spinocerebellar ataxia was negative. On basis of CSF TB-PCR report, she was given a trial of Anti Tubercular Drugs (ATDs) and was discharged. She returned after 2 months on follow-up and her unsteadiness in gait and dysarthria had improved.

**Discussion:** Tuberculosis remains a worldwide burden, especially in underdeveloped and developing countries like India. CNS disease by *Mycobacterium tuberculosis* is an uncommon yet dreadful manifestation of tuberculosis which accounts for approximately 1% of all cases of tuberculosis, and carries high mortality. Cerebellar involvement in tuberculosis was previously reported in literature, and can be due to tuberculomas, tuberculous meningitis, or cerebellitis. MRI and CSF findings in our patient were not suggestive of the first two possibilities and so, TB cerebellitis was the likely possibility.

**Conclusion:** We present a rare case of primary tuberculous cerebellitis from eastern India, which was diagnosed by CSF TB-PCR. In India, when a patient presents with chronic neurological symptoms, clinician must consider tuberculosis as an important differential diagnosis. CSF TB-PCR can be used as an important tool for diagnosis of CNS tuberculosis where other measures fail.

doi:10.1016/j.jns.2015.08.362

293

WFN15-1319

CNS Infections

Salmonella meningitis in peruvian infants. Clinical cases

J. Flores Bravo, P. Muñoz Huerta, V. Granados Alzamora, J. Montiel Blanco, E. Lazaro Ignacio, D. Koc Gonzales, I.N.E.S. Caro Kahn, N. Ramos Timana. *Neuropediatria, Instituto Nacional De Salud Del Niño, Lima, Peru*

**Objective:** To describe the clinical, neuroimaging findings and outcome of three infants with salmonella meningitis.

**Material and Methods:** Between 2013 and 2015 three 7 months old male infants were admitted to Instituto Nacional de Salud del Niño with subacute neurological symptoms: disturbance of consciousness, seizures and fever. Lumbar puncture was done obtaining a mononuclear pleocytosis and severe hypoglycorrhachia dominance in all cases. *Salmonella* sp. sensitive to conventional antibiotics was isolated from cerebrospinal fluid. *Salmonella*'s transmission pathways were related to ingestion of contaminated poached eggs in 2 infants and 1

family raised chickens. Neurological complication of the 3 cases showed extensive unilateral fronto parietal subdural effusion requiring surgical drainage in one case and in the other 2 cases was watchful waiting. 3 cases received prolonged systemic antibiotic therapy (90 days on average). The follow-up was by neuroimaging showed resolution of collections and serial CSF obtained by lumbar puncture showed progressive improvement in hypoglycorrachia and cellularity. The clinical outcome was favorable without motor or sensory deficits.

**Conclusion:** Salmonella meningitis in infants requires prolonged systemic antibiotic therapy and careful monitoring.

doi:10.1016/j.jns.2015.08.363

294

WFN15-0467

CNS Infections

**Clinical and epidemiological survey of gerstmann-sträussler-scheinker disease with codon 102 mutation in Japan**

H. Murai<sup>a</sup>, Y. Nakamura<sup>b</sup>, T. Kitamoto<sup>c</sup>, Y. Tsuboi<sup>d</sup>, N. Sanjo<sup>e</sup>, M. Yamada<sup>f</sup>, H. Mizusawa<sup>g</sup>, J. Kira<sup>a</sup>. <sup>a</sup>Neurology, Kyushu University, Fukuoka, Japan; <sup>b</sup>Public Health, Jichi Medical University, Shimotsuke, Japan; <sup>c</sup>Prion Protein Research, Tohoku University, Sendai, Japan; <sup>d</sup>Neurology, Fukuoka University, Fukuoka, Japan; <sup>e</sup>Neurology and Neurological Science, Tokyo Medical and Dental University, Tokyo, Japan; <sup>f</sup>Neurology and Neurobiology of Aging, Kanazawa University, Kanazawa, Japan; <sup>g</sup>Neurology, National Center of Neurology and Psychiatry, Kodaira, Japan

**Background:** Gerstmann-Sträussler-Scheinker disease (GSS) is a genetic prion disease harboring mutations in PRNP gene. GSS with codon 102 mutation (GSS102) is the most common type, and is more frequent in Japan than in Europe. It presents spinocerebellar degeneration-like feature (typical type), but there also exists a rapid progressive type.

**Objective:** To evaluate the clinical and epidemiological feature of GSS102 in Japan.

**Patients and Methods:** We collected information on clinical and epidemiological data of GSS102 analyzed by the CJD Surveillance Committee, Japan, from 1999 to 2014.

**Results:** A total of 80 GSS102 patients were extracted. Among them, 54 (68%) reside or born in Kyushu island which locates in south-west part of Japan. Within Kyushu Island, there were two large clustering of patients. Family history was observed in 68 (85%). Onset symptom was ataxia in 61% and dementia in 14%. Periodic synchronous wave complexes (PSWC) in EEG were observed only in 13%, hyperintense cortices in diffusion-weighted MRI, 39%. The 80% of the former and 61% of the latter developed akinetic mutism.

**Conclusion:** Approximately two thirds of GSS102 patients live or originate in Kyushu island, and there seem to be two large accumulated areas in the island. PSWC in EEG and hyperintensity in MRI could be a predictor of rapid progressive GSS102.

doi:10.1016/j.jns.2015.08.364

295

WFN15-0356

CNS Infections

**HTLV-1 complete genome analysis identified a risk subtype for HTLV-1-associated myelopathy/tropical spastic paraparesis and subtype-specific amino acid changes**

S. Nozuma<sup>a</sup>, E. Matsuura<sup>a</sup>, T. Matsuzaki<sup>b</sup>, O. Watanabe<sup>a</sup>, D. Kodama<sup>b</sup>, R. Kubota<sup>b</sup>, S. Izumo<sup>b</sup>, H. Takashima<sup>a</sup>. <sup>a</sup>Department of Neurology and Geriatrics, Kagoshima University Graduate School of Medical and Dental Science, Kagoshima, Japan; <sup>b</sup>Department of Molecular Pathology,

Kagoshima University Graduate School of Medical and Dental Science, Kagoshima, Japan

**Background:** Although HTLV-1 infection is prerequisite for development of HTLV-1-associated myelopathy/tropical spastic paraparesis (HAM/TSP), specific provirus mutations in HAM/TSP have not yet been reported.

**Objective:** To clarify the disease-specific variants in HTLV-1 sequence, we analyzed entire sequences of HTLV-1 proviruses.

**Patients and Methods:** Peripheral blood samples were studied from 30 familial HAM/TSP (f-HAM/TSP), 92 sporadic HAM/TSP (s-HAM/TSP), and 89 asymptomatic carriers (ACs). DNA was extracted from PBMCs and HTLV-1 complete provirus genome was amplified by nested PCR. The amplified PCR products were screened on the Miseq sequencing system and the sequencing data were aligned and mapped against the HTLV-1 genome and utilized for constructing phylogenetic tree and identifying possible mutations.

**Results:** In 211 samples, 37 samples were classified into transcontinental subtype and 174 were Japanese subtype. The frequency of transcontinental subtype was significantly higher in HAM/TSP than in ACs. Among three groups, the ratio of transcontinental subtype in f-HAM/TSP, s-HAM/TSP and ACs was 33%, 23% and 7%, respectively. The frequency of transcontinental subtype was significantly higher in HAM/TSP, especially in f-HAM/TSP than in ACs ( $p = 0.001$ ). We could not detect any specific mutations in HAM/TSP. However, ten mutations causing the amino acid changes specific to transcontinental subtype in the HTLV-1 provirus genes were identified.

**Conclusion:** Transcontinental subtype is more frequent in HAM/TSP, especially in familial cases. Ten common mutations altering amino acid changes in transcontinental subtype compared with Japanese subtypes are detected and implicated in development with HAM/TSP.

doi:10.1016/j.jns.2015.08.365

296

WFN15-0853

CNS Infections

**Clinical, laboratory, pathological and therapeutical study in a series of 16 cases of spinal neurocysticercosis**

H. Nuñez Villegas<sup>a</sup>, C. Nuñez Daza<sup>a</sup>, R.J. Verdugo Latorre<sup>b</sup>, S. Condori Montes<sup>c</sup>, J.M. Matamala Capponi<sup>d</sup>, S. Rodriguez<sup>e</sup>, R. Quiroga<sup>f</sup>, N. Asseff<sup>g</sup>, A. Zambrana<sup>g</sup>. <sup>a</sup>Neurología, Caja Nacional de Salud, Cochabamba, Bolivia; <sup>b</sup>Neurología, Clínica Alemana, Santiago, Chile; <sup>c</sup>Medicina Interna, Caja Petrolera de Salud, Cochabamba, Bolivia; <sup>d</sup>Ciencias Neurológicas, Facultad de Medicina de la Universidad de Chile, Santiago, Chile; <sup>e</sup>Neurología, Hospital J.M. Ramos Mejía, Buenos Aires, Argentina; <sup>f</sup>Neurocirugía, Clínica Los Olivos, Cochabamba, Bolivia; <sup>g</sup>Private Medical Consultation, Private Medical Consultation, Cochabamba, Bolivia

**Background:** Neurocysticercosis (NCC) is the most common helminthic infection of the central nervous system. The disease is endemic in most of the developing world with a prevalence of 8% to 25%. The incidence in Bolivia is 350 a 450 per 100.000. Spinal cord involvement is uncommon being reported in 1.2% to 5.8% of patients.

**Patients and methods:** We analyzed 16 consecutive patients with spinal NCC seen in Cochabamba, Bolivia between 1990 and 2014. The diagnosis of spinal NCC was defined as the presence of compatible lesions in the CT scan or MRI and positive ELISA test in CSF or pathological study.

**Results:** The average (SD) age was 48.2 (18.21904) years. Spastic tetra or paraparesis was the presenting complain and the main finding in neurological examination in 14 patients. Syringomyelic sensory dissociation was found in 7 patients. Intraependymal lesions were present in 7 cases and leptomeningeal involvement in 8. One case had both. Thoracic spine was involve in 10 cases. Eleven patients had



pathology confirmation. Two cases were treated surgically, 3 with albendazole, 9 with both and two untreated. Improvement of weakness or sensory symptoms occurred in 6 cases, worsening in 6, no change in 2 and 1 unknown evolution. One patient died postoperatively. Brain lesions were found in 5 patients.

**Conclusion:** To our knowledge this is the largest series of spinal NCC, which is a cause of severe disability. Surgery and albendazole may be suitable therapies but the role of each therapy in intrapendimary and leptomeningeal must be defined.

doi:10.1016/j.jns.2015.08.366

297

WFN15-1556

CNS Infections

**Neurologic manifestations of neurocryptococcosis in immunocompetent patient: report of a case with evolution clinical without sequelae**

L.S.A. Rocha, R.G.C. Pinto, A.C.S. Maiolini, R.F.S. Goncalves, P.F.S. Goncalves, R.C. Silva Junior, P.O.L. Landim, E.B.S. Reis, S.R. Rossi, R.M. Feltrin. *Hospital Universitario De Cuiaba, Universidade de cuiaba, Cuiaba, Brazil*

**Introduction:** Cryptococcosis is a fungal infection with predilection for the central nervous system (CNS), rarely affects immunocompetent, its highest incidence is in immunocompromised, especially in tropical and subtropical areas endemic for the disease. Headache and fever are present, being meningoencephalitis the most common clinical form, can develop serious neurological sequelae and death.

**Objective:** To report a case of cryptococcal meningitis in an immunocompetent patient.

**Report:** C.C.O, female, 44, previously healthy, taken to São Matheus Hospital with holocranial intense headache, dizziness and vomiting, 1 week ago, with progressive worsening. The physical examination showed her awake, oriented, with bilateral convergent strabismus, loss of balance and ataxia. Immunocompetent with negative rapid test for HIV. CT scan (CT) and brain Magnetic Resonance Imaging (MRI) showed expansive lesions in the posterior fossa with compressive effect on the fourth ventricle, the collection of cerebrospinal fluid (CSF) found encapsulated yeast, with positive India ink, diagnosing cryptococcosis. She was treated with cefuroxime and ambisome. It evolved with intracranial hypertension (IH), hydrocephalus, and after external ventricular drain (EVD) presented clinical stability. The patient developed meningoencephalitis, treated with ambisome, vancomycin and Tazocin. Today is stable, awake, afebrile and sterile CSF and without sequelae.

**Discussion/Conclusion:** The purpose of this case is to show the need and the importance of neurocryptococcosis research on immunocompetent patients, and its inclusion as a differential diagnosis on these. Knowing that early intervention can prevent the occurrence of permanent neurological sequelae, such as mental impairment, reduced visual acuity, cranial nerve palsy and hydrocephalus.

doi:10.1016/j.jns.2015.08.367

298

WFN15-0425

CNS Infections

**Opportunistic neuroinfections in retroviral disease - retrospective hospital-based study from india**

N. Panpalia, K. Naik, A. Saroja, D. Doshi. *Neurology, KLE University's Jawaharlal Nehru Medical College, BELGAUM, India*

**Background:** Patients with retroviral disease are prone for opportunistic infections which are significant cause of mortality and morbidity. Cryptococcosis, tuberculosis and toxoplasma are the commonest infections occurring at all stages of the disease.

**Objective:** This study was undertaken to evaluate the pattern of opportunistic infections and in hospital mortality in AIDS patients.

**Methods:** This retrospective analysis was done in tertiary care hospital from 2001-2014 services. Details of clinical profile and laboratory investigations of patients admitted under neurological services with neuroinfections were studied.

**Results:** There were 167 patients with 131 men and 36 women (ratio 3.63:1). Their age ranged from 16 to 67 years ( $39.25 \pm 8.85$ ). Clinical presentation was acute in 58%, subacute in 32% and chronic in 10%. Fever (65.86%) and headache (86.82%) were common symptoms. Seizures were present in 25% of the patients and altered sensorium in 37%. Among the neuroinfections cryptococcal meningitis was the commonest etiology accounting for 40%. Other infections included tuberculosis (19%), viral (20%), mixed tubercular and fungal (13%) and toxoplasmosis (6%). PML was seen in 10%. Dyselectrolyemia was seen in 16.76% patients. Fifteen patients died during admission (9%). Twenty patients had cerebral granulomas. Mortality was the highest in cryptococcal meningitis (46.6%) followed mixed infection (26.6%), neurotuberculosis (13.3%) and viral etiology (13.3%). Complication at the onset and during the course consisted of renal dysfunction in 19, uncontrolled seizures in 16 patients, and hepatic dysfunction in 11 patients.

**Conclusion:** Commonest opportunistic infection in AIDS patients is cryptococcal meningitis. Others being neurotuberculosis, progressive multifocal leucoencephalopathy and toxoplasmosis.

doi:10.1016/j.jns.2015.08.368

299

WFN15-0330

CNS Infections

**27 cases of atypical viral encephalitis with obvious psychiatric symptom but negative auxiliary diagnosis**

X.K. Qi<sup>a</sup>, J.G. Liu<sup>a</sup>, C.Q. Li<sup>b</sup>, B.O. Ning<sup>a</sup>. <sup>a</sup>Department of Neurology, Navy General Hospital of PLA, Beijing, China; <sup>b</sup>Department of Neurology, Beijing Chaoyang Hospital (Jingxi Campus), Beijing, China

**Objective:** To summary the clinical and therapeutic features of atypical viral encephalitis with obvious psychiatric symptoms but negative auxiliary diagnosis in 27 patients.

**Methods:** The clinical manifestation, neuroimaging, electroencephalography, blood, cerebrospinal fluid features and therapeutic effect of 27 cases of atypical viral encephalitis with obvious psychiatric symptoms were analyzed retrospectively.

**Results:** The onset age of 27 patients (male 19, female 8) ranged from 14 to 60 (mean  $29.93 \pm 12.77$ ) years old. Psychiatric symptoms were common in the disease onset (17 cases). All cases suffered from disturbance of consciousness, including with varying degree of consciousness clarity in 20 cases and delirium in 8 cases. The cranial imagery, electroencephalography, ambulatory electroencephalography, the routine and biochemistry examination of cerebrospinal fluid, the virus of blood and cerebrospinal fluid were all normal. It's easy to be misdiagnosed as schizophrenia (11 cases) and depression (4 cases). After long period antiviral treatment (3-14 weeks), all patients had good prognosis.

**Conclusions:** Though their etiological evidence could not be detected, the diagnosis of VE could not be excluded absolutely if the patients had obvious psychiatric symptoms but not neurological symptoms and signs. Sufficient dosage and treatment course is very

important for antiviral treatment, and it should be attempted and then observing its curative effects when suspected VE.

doi:10.1016/j.jns.2015.08.369

300

WFN15-1503

CNS Infections

**Mycoplasma pneumonia presenting with bilateral optic papillitis and acute inflammatory demyelinating polyradiculopathy**

A.L. Ross Russell, C. Mitchell, S. Farmer. *Neurology, National Hospital for Neurology and Neurosurgery, London, United Kingdom*

We present a 39 year old female presenting with progressive visual loss and retro-orbital pain over a ten day period, following an episode of frontal headache. Examination of her eyes revealed absent perception of light and absent pupillary reflexes bilaterally with normal, pain-free eye movements. Fundoscopy demonstrated bilateral optic disc swelling with splinter haemorrhages.

Our patient described concurrent, non-progressive numbness of her fingers and toes, with associated pain but no appreciated weakness. Examination revealed mild, bilateral weakness in a non-pyramidal distribution, and length-dependent, decreased light-touch and pinprick sensation.

CSF showed a protein of 0.21 g/L with paired oligoclonal bands. Culture and cytology were negative. Auto-antibodies including HIV, aquaporin 4 and anti-neuronal were negative. MRI showed enlargement and avid enhancement of both optic nerves. PET-CT was unremarkable. Nerve conduction studies confirmed a motor predominant, distal, demyelinating polyneuropathy. Mycoplasma serology was positive, with a titre of 1:20480.

Our patient showed no response to IV methylprednisolone and subsequently received five courses of plasma exchange with significant clinical, radiological and electrophysiological improvement. At discharge her visual acuities were 6/18 and 6/9.

Convalescent serology at one week and one month showed a consistent titre of 1:1280, confirming recent exposure at initial presentation. We therefore propose a diagnosis of acute mycoplasma pneumonia with associated parainfectious, bilateral, optic papillitis and inflammatory demyelinating polyradiculopathy.

Although multiple neurological sequelae of mycoplasma infection are recognised, there is only one previously reported case of an acute demyelinating polyneuropathy occurring with serological evidence of mycoplasma infection.

doi:10.1016/j.jns.2015.08.370

301

WFN15-0573

CNS Infections

**Meningitis in acute paracoccidioidomycosis in a hiv positive patient**

S.M. Almeida<sup>a</sup>, T.H. Roza<sup>a</sup>, G.L. Oliveira Salvador<sup>a</sup>, A.H. Aragão<sup>a</sup>, L.V. Oliva<sup>a</sup>, J.B. França<sup>b</sup>, M.K. Franco Pedro<sup>a</sup>, L. Noronha<sup>a</sup>, L.F. Bleggi Torres<sup>a</sup>. <sup>a</sup>Department of Medical Pathology, Universidade Federal do Paraná, Curitiba, Brazil; <sup>b</sup>Department of Infectious Diseases, Hospital de Clínicas da Universidade Federal do Paraná, Curitiba, Brazil

**Background:** Paracoccidioidomycosis (PCM) is a fungal disease caused by *Paracoccidioides brasiliensis*. Meningitis in neuro PCM is rare, being more frequent in the acute form.

**Objective:** Case report of meningitis by *P.brasiliensis* in an immunodepressed patient.

**Patient and Methods:** A 30 years old man with history of weight loss, dry cough, fever and night sweats with three months of duration; dysphagia of 15 days of duration; consciousness reduction, psychomotor agitation and acute respiratory failure with two days of duration. Clinical examination: disseminated macules and papules, splenomegaly, lymph nodes swollen. Glasgow 13/15, no meningeal signs. He evolved with respiratory distress, consciousness reduction, shock, respiratory failure, refractory hemodynamic instability, renal failure and death less than 24 hours after admission. We have obtained IRB approval, as necessary.

**Results:** Brain TAC with hyperintense images indicated haemorrhage in parietal lobes. Hemogram: pancytopenia (hemoglobin of 8.5 g/dL, WBC count of 1.27x10<sup>6</sup>/μL, platelet count 81,000/μL). The CSF analysis did not show any cellular or biochemical alteration. HIV diagnosis positive with ELISA and confirmed with Western Blot (post mortem). CNS autopsy: PCM meningitis and toxoplasmosis mass lesions. The systemic autopsy: acute form of PCM in lungs, heart, liver, spleen, lymph nodes, thyroid, kidneys, adrenal gland, skin and intestinal wall. Other etiologic agents were diagnosed: *Histoplasma capsulatum*; *Candida sp.* and Cytomegalovirus.

**Conclusion:** The association between PCM and HIV is rare; the clinical course of PCM, in HIV patients, resembles an acute infection. Meningitis caused by PCM is rare in the chronic infection, being more common in the acute form.

doi:10.1016/j.jns.2015.08.371

302

WFN15-0574

CNS Infections

**Paracoccidioidomycosis with central nervous system involvement, a retrospective analysis of autopsy reports, 63 years experience of a Brazilian university hospital**

S.M. Almeida, T.H. Roza, G.L. Oliveira Salvador, A.H. Aragão, L.F. Izycki, L. Noronha, L.F. Bleggi Torres. *Department of Medical Pathology, Universidade Federal do Paraná, Curitiba, Brazil*

**Background:** Paracoccidioidomycosis (PCM) is a fungal infection caused by *Paracoccidioides brasiliensis*. Central Nervous System (CNS) involvement, neuroparacoccidioidomycosis (NPCM), occurs in 13% of the cases. HIV patients develop a more severe and acute variant of the disease.

**Objective:** Description of the frequency, and clinical presentation, of systemic PCM, NPCM and the co-infection with HIV/AIDS, at a Brazilian university hospital.

**Material and methods:** Retrospective analysis of autopsy reports, between 1951 and 2014, in which PCM/NPCM and/or HIV/AIDS were the primary or secondary cause of death. The medical records of the patients were reviewed. We have obtained Institutional Review Board approval, as necessary.

**Results:** In the 63 years, 13,986 autopsy reports were analyzed. There were nine cases of PCM (0.06% of the total of reports), NPCM was found in one case (11%) of the PCM total cases. Among all HIV cases only one was co-infected with PCM, 1/32 (3.1%). The case with NPCM was the same with HIV, presenting meningitis by *P. brasiliensis* and an acute form of PCM. Eight out of the nine PCM cases were reported in males (89%). The age (mean±SD) was 48.11 ± 12.17 years.

**Conclusion:** NPCM prevalence in PCM cases is consistent with previous studies. The prevalence of PCM, in this study, was much higher in males in comparison with females, as reported previously. The incidence of PCM in HIV is low.

doi:10.1016/j.jns.2015.08.372



303

WFN15-0487

## CNS Infections

## Cerebellar atrophy by the jc virus in a patient with aids

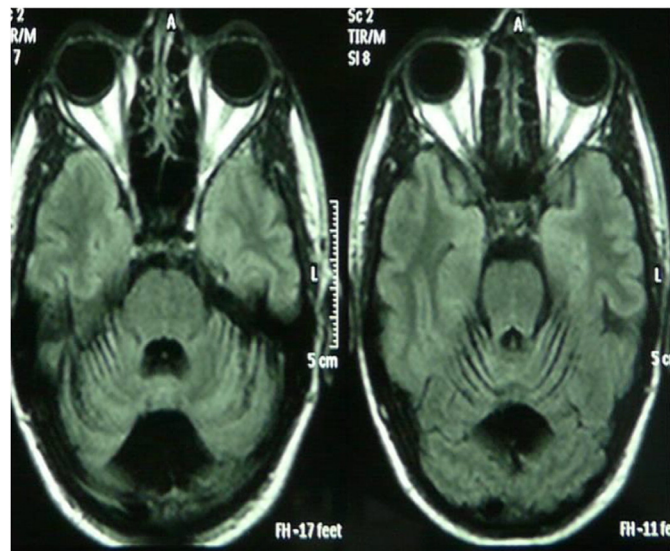
C. Silva. *Neurology-Neurosurgery, University of Chile, Santiago, Chile*

JVC causes the progressive multifocal leukoencephalopathy (PML). At least 5% of AIDS patients may develop PML. However a JVC variant attacks the granular cells of cerebellum only, among patients infected with HIV as well. This rare condition causes a progressive cerebellar syndrome and a marked atrophy of the cerebellum on MRI, without the characteristic lesions in the white matter of the PML. The natural history of this disease causes the death of the patient without having an effective treatment to date.

It presents a 34 years old Hispanic man, with dizziness, gait disturbances, and a scanned speech consistent with a cerebellar syndrome of 6 months duration. The brain MRI showed diffuse cerebellar atrophy, noting the absence of white matter lesions. He was diagnosed HIV / AIDS at stage C3, with CD4 + of 52 and a serum viral load of 27,000. He started with antiretroviral therapy (HAART). The CSF was normal except for the PCR positive for the JCV. At 4 months, and despite HAART, the patient had a progression of his cerebellar syndrome, adding a severe vestibular syndrome, characterized by the inability to walk and profuse vomiting. The cerebellar atrophy increased in the brain MRI control. There was a clear recovery of the immunological parameters (CD4+ and HIV serum viral load) at this time. The follow up of the patient at 7 months showed a partial regression of cerebellar symptoms, especially with respect to dizziness and vomiting.

1. Igor J. Koralnik et al. JC Virus Granule Cell Neuronopathy: A Novel Clinical Syndrome Distinct from Progressive Multifocal Leukoencephalopathy. *Ann Neurol* 2005;57:576–580.

2. R.A. Du Pasquier et al. Productive infection of cerebellar granule cell neurons by JC virus in an HIV individual. *Neurology* 2003;61:775–782.



doi:10.1016/j.jns.2015.08.373

304

WFN15-0072

## CNS Infections

## Herpetic infection and anti-varicella-zoster virus antibodies in multiple sclerosis patients treated with fingolimod

P. Stourac, M. Svobodova, P. Praksova. *Neurology, Masaryk University Faculty of Medicine, Brno, Czech Republic*

**Background:** Patients should be tested for antibodies against varicella zoster virus (VZV) prior to fingolimod treatment. One fatal case of VZV infection was reported in a seronegative patient receiving fingolimod. Anti-VZV specific antibody evolution during fingolimod treatment and its relevance to infections are not fully elucidated.

**Objectives:** The aims of our study were to evaluate dynamics of immune response in IgM and IgG antibody classes against VZV in multiple sclerosis (MS) patients before and during fingolimod therapy and to review the occurrence of infections

**Patients/Methods:** Twenty-five MS patients in our cohort were treated with fingolimod. Specific anti-VZV IgG and IgM antibodies were detected by chemiluminescent immunoassay (Liaison® VZV IgG, VZV IgM) prior to therapy and after 12 months. Antibody levels were expressed for IgM class as antibody index (cut-off value 1.0) and for IgG class in mIU/ml (cut-off value 150 mIU/ml). Statistics were done by Wilcoxon test.

**Results:** VZV IgM indices did not significantly change (range between 0.1–0.38), p-value 0,234. VZV IgG antibody levels significantly increased during observation (values range between 398.6–4000), p-value 0.030. One patient developed herpes zoster infection paralleled by significant increase in IgG antibody level, but not in IgM class. The patient was treated with acyclovir. There were no other complications of herpetic infection and the patient continues with treatment under surveillance.

**Conclusion:** Significant elevation of specific anti-VZV IgG antibodies under fingolimod treatment was proven. One case of herpetic infection was diagnosed. Continuous clinical and immunological surveillance of fingolimod treated patients is recommended.

doi:10.1016/j.jns.2015.08.374

306

WFN15-1280

## CNS Infections

## Neuroborreliosis (lyme disease): report on five patients aged between 10 and 30 years residing in northeastern Mexico presenting atypical symptomatology

J. Trevino<sup>a</sup>, R. Calderon-Sepúlveda<sup>a</sup>, A. Yee-Arellano<sup>b</sup>, M. Peral-Ríos<sup>a</sup>, J.A. Trevino-Calderon<sup>c</sup>. <sup>a</sup>*Neurology, Escuela de Medicina y Ciencias de la Salud Tecnológico de Monterrey, Monterrey, Mexico*; <sup>b</sup>*Infectology, Escuela de Medicina y Ciencias de la Salud Tecnológico de Monterrey, Monterrey, Mexico*; <sup>c</sup>*Medical Student, Escuela de Medicina y Ciencias de la Salud Tecnológico de Monterrey, Monterrey, Mexico*

**Background:** Lyme disease (LD) is a multisystemic vector-borne diseases caused by *Borrelia* spp. and transmitted by Ixodes tick. There is a 15% reported prevalence on northeastern Mexico with a highly underestimated disease burden. The clinical presentation is variable, and can develop up to 12 weeks after infection. The most frequent neurological symptomatology involves painful meningoradiculitis and cranial nerve palsy.

**Objective:** Report on the presence of atypical neurological symptoms of neuroborreliosis in five patients between 10 and 30 years of age.

**Patients and methods:** We present a retrospective descriptive study of five cases with atypical neurological findings and posterior *Borrelia burgdorferi* confirmation by laboratory evaluation. Two cases presented with recurrent headache, paresthesia and symmetric progressive lower limb weakness. In other case the clinical presentation involved muscle weakness worsened by physical activity, orthostatic hypotension which led to syncope, ataxia and diaphragmatic weakness. An additional case presented with symptomatology suggesting meningoencephalitis. Finally the 5th patient presented with symptoms suggesting encephalitis.

**Results:** Findings in all patients included: LCR pleocytosis, negative LCR culture, serum *Borrelia burgdorferi* confirmation, MRI which

demonstrated normal findings, absence of intrathecal antibody production and a favorable response to antibiotic treatment with Doxycycline and Ceftriaxone resulting in ad integrum recovery. 3 patients developed Post LD Syndrome in a 6 month window period post ad integrum recovery.

**Discussion:** It is of importance to consider the possibility of borreliosis in endemic areas due to its prevalence, variable clinical presentation and tendency to mimic and accompany other diseases.

doi:10.1016/j.jns.2015.08.375

307

WFN15-0106

CNS Infections

**Evaluation of remediation and compensation strategies for HIV-associated neurocognitive disorders: a review of the state of the science**

*D. Vance, School of Nursing, University of Alabama at Birmingham, Birmingham, USA*

**Background:** Approximately 56% of adults with HIV experience Frascati-defined HIV-Associated Neurocognitive Disorder (HAND) which negatively impacts everyday functioning (i.e., driving) and results in increased morbidity and mortality. With 70% of the HIV population being 50 and older by 2020, this sparks concerns about co-occurring age-related neurocognitive declines exacerbating HAND.

**Objective:** This meta-review examines the mechanisms in which HIV compromises neurocognition. Specifically, the role of macrophages and infection of glia in producing neuroinflammation will be briefly reviewed within the context of the neurocognitive reserve hypothesis and lifespan neurocognitive development. From this, remediation and compensation strategies found in the literature are reviewed and evaluated.

**Method:** Several studies are examined for their efficacy in improving and protecting neurocognitive functioning in adults with HIV. Considerations for sample size, length of treatments, and other such study-related factors are considered. Studies presented have IRB approval.

**Results:** Several strategies have been shown to protect or improve neurocognitive functioning in adults with HIV including: 1) combination antiretroviral therapy; 2) treatment of comorbidities and mood disorders; 3) psychostimulants (i.e., methylphenidate) and neuroprotective agents (i.e., lithium); 4) cognitive remediation therapy; and 5) certain lifestyle factors (i.e., physical exercise, social engagement). Other approaches shown not to be effective include: 1) acetylcholinesterase inhibitors; and 2) anti-inflammatory medications. In lieu of such neurocognitive disorders, compensation strategies (i.e., mnemonic, spaced-retrieval method) are provided.

**Conclusion:** Several strategies can improve or protect neurocognitive functioning in adults with HIV. Future approaches such as cognitive prescriptions and transcranial direct current stimulation are explored as potential, novel research vectors.

doi:10.1016/j.jns.2015.08.376

308

WFN15-0107

CNS Infections

**An examination of the relationship between neurocognition and self-reported coping behaviors in adults with and without HIV**

*D. Vance, S. Cody, School of Nursing, University of Alabama at Birmingham, Birmingham, USA*

**Background:** Approximately 52%-56% of adults with HIV experience Frascati-criteria HIV-Associated Neurocognitive Disorder (HAND)

which negatively affects performance on everyday activities such as driving and medication adherence. In particular, the fronto-striato-thalamo circuitry is particularly compromised in adults with HIV. This results in compromised procedural memory and executive/reasoning deficits. Likewise, fronto-striato circuitry dysfunction may predispose such individuals to emotional initiative and perseveration problems that may compromise one's ability to engage in proactive coping behaviors, which is particularly needed to negotiate many challenges associated with HIV.

**Objective:** The purpose of this study is to examine what neurocognitive (i.e., executive functioning) and psychosocial factors are related to self-reported proactive coping in adults with and without HIV.

**Method:** A comprehensive neuropsychological and psychosocial battery (i.e., Proactive Coping Behavior Scale) was administered to 98 adults with HIV and 103 adults without HIV in this cross-sectional study. A series of hierarchical multiple regressions were used to determine the predictors of proactive coping. This study received IRB approval for human subjects.

**Results:** In adults with HIV, proactive coping was related to religiosity/spirituality ( $p=.000$ ); in adults without HIV, proactive coping was related to religiosity/spirituality and faster speed of processing ( $p=.018$ ). Compared to the adults without HIV, post-hoc analyses demonstrated that adults with HIV had poorer neurocognitive functioning and higher neurocognitive dispersion.

**Conclusions:** Although executive functioning was not found to contribute to proactive coping behavior in adults with HIV, group comparisons found that adults with HIV exhibited a poorer neurocognitive phenotype suggesting a need for neurocognitive intervention.

doi:10.1016/j.jns.2015.08.377

309

WFN15-0118

CNS Infections

**Neurocognitive predictors of driving in older adults with HIV: a driving simulator study**

*D. Vance, S. Cody, C. Nicholson, J. Palmer, School of Nursing, University of Alabama at Birmingham, Birmingham, USA*

**Background:** Using Frascati-criteria, 52-56% of adults with HIV have HIV-Associated Neurocognitive Disorder (HAND). HAND results from fronto-striato-thalamo circuitry, hippocampus, and temporal lobe atrophy. HAND may also impair everyday functioning, including driving, especially as this population ages and experiences age-related cognitive declines.

**Objective:** This study examined what neurocognitive domains are related to driving behavior, as measured by a driving simulator, in older adults with HIV.

**Method:** In this cross-sectional IRB approved study, a neurocognitive battery along with a driving simulator protocol was administered to 27 middle-aged and older adults with HIV ( $M=51.38$  years;  $range=41-67$  years). Neurocognitive measures included Trails A and Finger Tapping Test (psychomotor), Useful Field of View (visual speed of processing), Hopkins Verbal Learning Test (verbal memory), and Trails B (executive functioning). Several hierarchical regressions were performed: step 1 controlled for age and education while the neurocognitive measures were entered for step 2. The dependent variables were provided by the driving simulator (e.g., number of collisions, number of pedestrians hit, etcetera).

**Results:** In model one ( $R\text{-square}=.53$ ), UFOV ( $p=.015$ ) predicted total number of stop signs missed. In model two ( $R\text{-square}=.43$ ), UFOV ( $p=.035$ ) predicted gross reaction time in the simulator. In model three ( $R\text{-square}=.59$ ), Trails A ( $p=.009$ ) and UFOV ( $p=.003$ ) predicted percentage of total distance of driving outside of the lane.

**Conclusions:** Speed of processing was particularly predictive of driving performance. Prior studies suggest that speed of processing training can improve this neurocognitive ability and improve driving in older adults; such an approach may also translate to those with HIV.

doi:[10.1016/j.jns.2015.08.378](https://doi.org/10.1016/j.jns.2015.08.378)

---

311

WFN15-1168

CNS Infections

**Sandfly fever virus meningoencephalitis imported from the island of elba, italy, to germany with a focus on cerebrospinal fluid findings**

B.T. Wollweber<sup>a</sup>, F. Weber<sup>b</sup>, M. Uhr<sup>b</sup>. <sup>a</sup>Psychiatry, Max-Planck-Institute of Psychiatry, München, Germany; <sup>b</sup>Neurology, Max-Planck-Institute of Psychiatry, München, Germany

**Background:** Sandfly fever virus infection leads to a central nervous system infection in a minority of cases.

**Objective:** We report about a case of sandfly fever virus meningoencephalitis imported from Elba into Germany with a focus on cerebrospinal fluid (CSF) findings.

**Patients and methods:** A 45-year-old male presented with fever up to 39.3°C, cough, headache, and onset of apathy after a holiday on the island of Elba. On admission to the emergency care unit third-party anamnesis revealed that the patient had suffered from flu-like symptoms for four days.

**Results:** CSF showed an elevated cell count (440/μl), elevated CSF/serum albumin ratio ( $39.9 \cdot 10^{-3}$ ), and local synthesis of IgA in the CNS. The patient was treated with acyclovir, ceftriaxone, and ampicillin. Further CSF examinations revealed a decline of cell count and CSF/serum albumin ratio, but an ongoing local CNS IgA synthesis. All CSF samples were negative for bacteria, fungi, and protozoa. Polymerase chain reaction was negative for Herpes simplex virus type 1/2, Varicella zoster virus, Cytomegalic virus, and Epstein Barr virus. A line blot for sandfly fever virus revealed positive serum IgM and IgG. The patient was discharged fully remitted after fourteen days. A follow up examination will be presented.

**Conclusion:** To our knowledge this is the third report about sandfly fever virus infection acquired on Elba and the first report about sandfly fever virus meningoencephalitis imported from Elba to Germany. Furthermore, our case report shows for the first time local IgA synthesis in the CNS in sandfly fever virus meningoencephalitis.

doi:[10.1016/j.jns.2015.08.379](https://doi.org/10.1016/j.jns.2015.08.379)

---